

# CHAPTER 14.1 – TYPES OF SKELETONS

## Types of skeletons

- The skeletal system provides support to humans and animals
- There are **three types** of skeletons
  - Exoskeleton
  - Endoskeleton
  - Hydrostatic skeleton

## The necessity of skeletal systems in animals and human

- To **enable** them to move from one place to another in search of food, partners, or to **escape** from predators and threats

- Most multicellular organisms need support because their soft body tissues

### EXOSKELETON

- ◇ The exoskeleton **found** in insects and crabs
- ◇ **Support** and **protect** body organs
- ◇ **Enable** these animals to move

### HYDROSTATIC SKELETON

- ↗ Found in earthworms
- ↗ To **maintain** a rigid body shape

### ENDOSKELETON

- ✚ To **maintain** body shape
- ✚ **Support** soft body tissues
- ✚ **Protect** internal organs from injury

# CHAPTER 14.2 – MUSCULOSKELETAL SYSTEM OF HUMANS

## Skeletal system

→ The human skeletal system is made up of

- i) Axial skeleton
- ii) Appendicular skeleton

## APPENDICULAR SKELETON

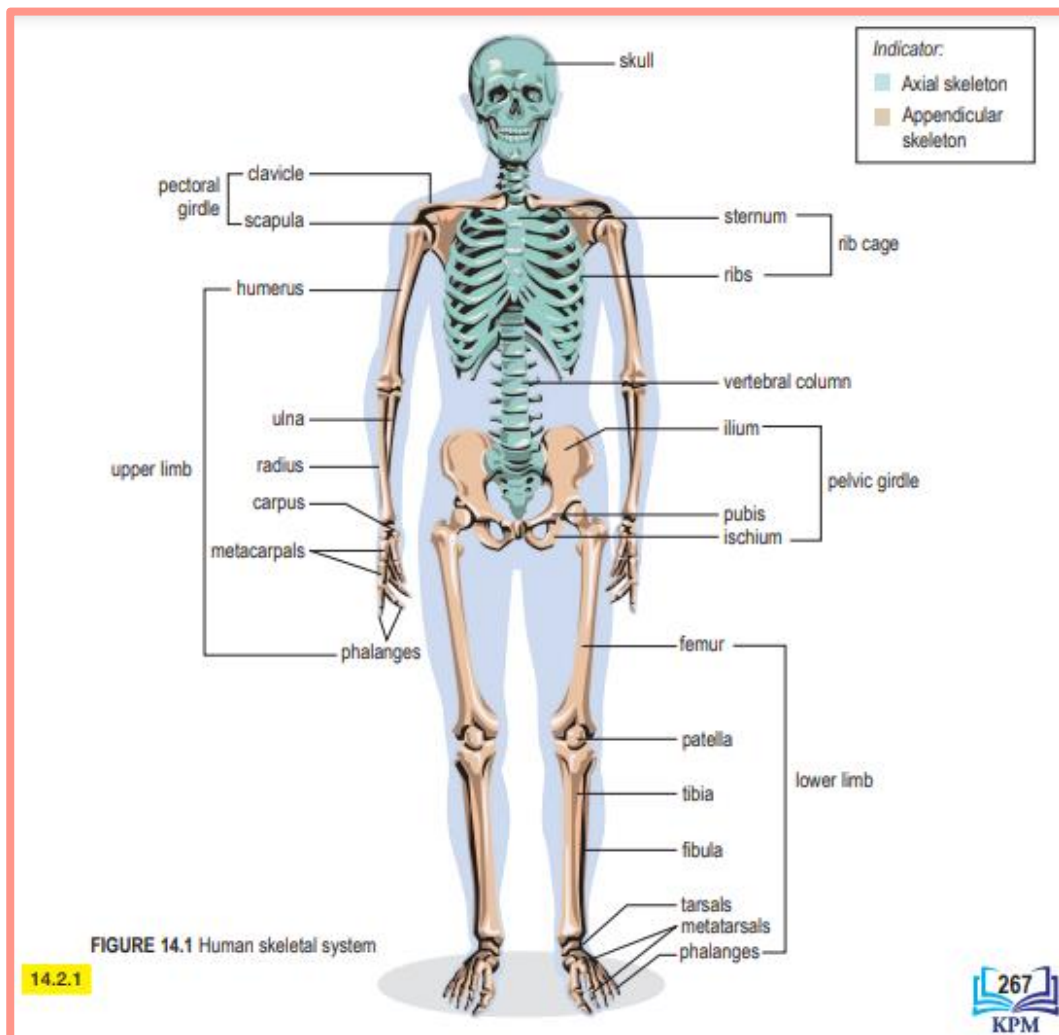
Δ The appendicular skeleton includes

- a) Pectoral girdle
- b) Pelvic girdle
- c) Upper limbs
- d) Lower limbs

## AXIAL SKELETON

⊕ The axial skeleton comprises

- 1 Skull
- 2 Vertebral column
- 3 Ribs
- 4 Sternum (breastbone)

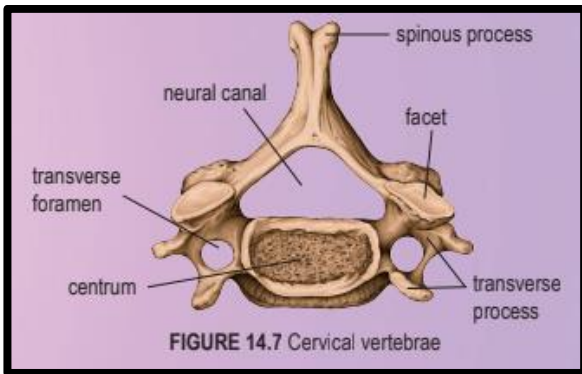


# Human vertebral column

- The vertebrae (singular: vertebra) on different parts of the vertebral column differ in size and shape
- Each vertebra has an opening known as the neural canal
- The spinal cord is located in the neural canal

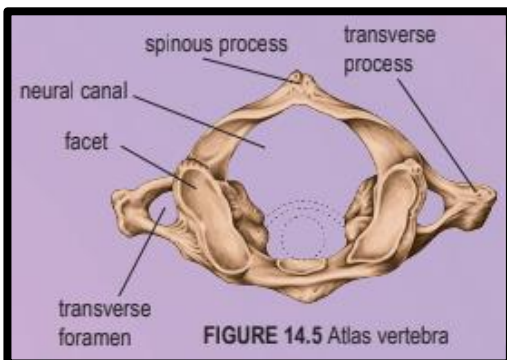
## CERVICAL VERTEBRAE

- ♥ Possess short spinous process, small centrum, wide and short transverse process, and a pair of transverse foramina



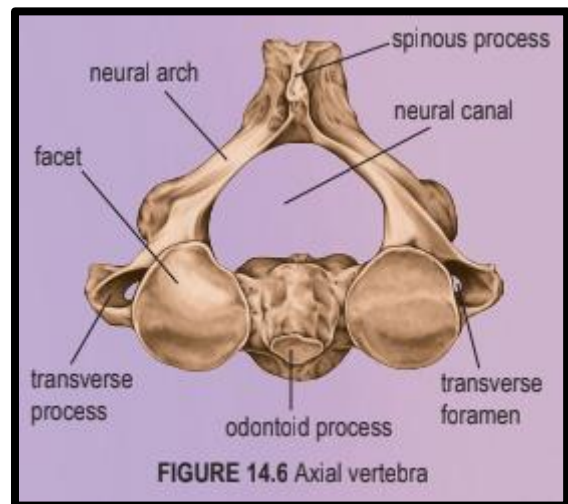
## ATLAS VERTEBRA

- ⊞ The first cervical vertebra
- ⊞ The vertebra has a large neural canal, a small spinous process, a pair of transverse foramina (singular: foramen) but with no centrum
- ⊞ The vertebra articulates with the skull



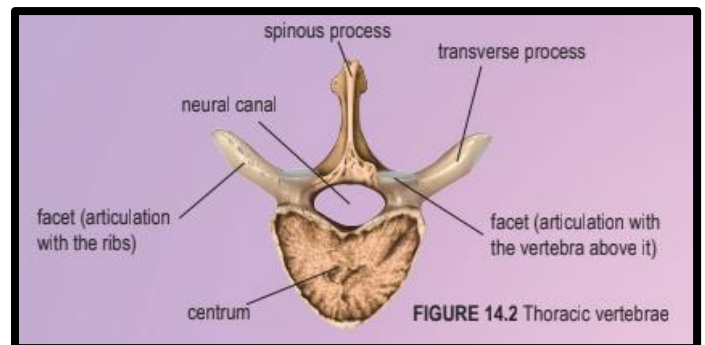
## AXIAL VERTEBRA

- ✓ The second cervical vertebra
- ✓ The axial vertebra has a large spinous process, small transverse process and a pair of transverse foramina
- ✓ It has an odontoid process that articulates with the facet of the atlas vertebra's neural canal



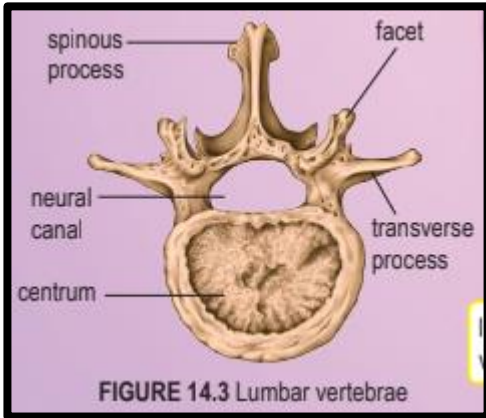
## THORACIC VERTEBRAE

- » Possess a long spinous process
- » Spinous and transverse processes serve as attachment sites for muscles and ligaments
- » The transverse processes (except on the 11<sup>th</sup> and 12<sup>th</sup> thoracic vertebrae) have facets for articulation with the ribs



**LUMBAR VERTEBRAE**

- ⇒ The **biggest** and **strongest** vertebrae
- ⇒ Possess a **short spinous process**
- ⇒ Possess a **large centrum** to bear the weight of the lower back of the body

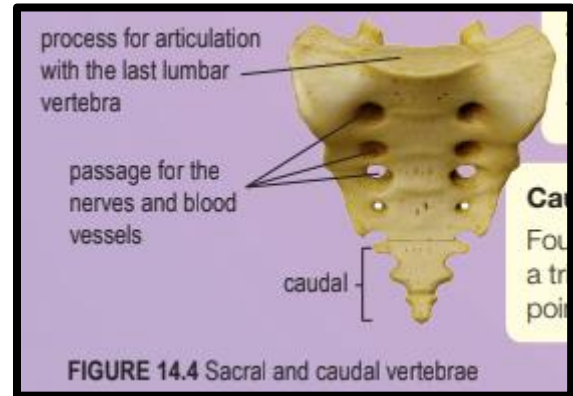


**SACRAL VERTEBRAE**

- ❖ Five vertebrae fused together to form a triangular bone

**CAUDAL VERTEBRAE**

- Four bones fused together to form a triangular structure which is pointed at one end



**SIMILARITY BETWEEN VERTEBRAE**

SIMILARITY	
○ All the vertebrae have	
	a) spinous and transverse processes
	b) centrum (except the atlas vertebra)
	c) neural canal

**DIFFERENCES BETWEEN VERTEBRAE**

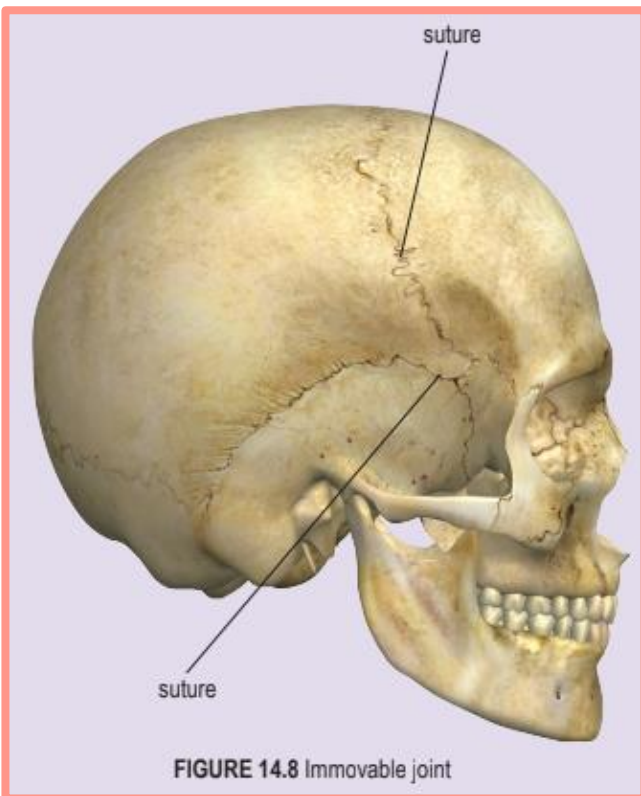
CHARACTERISTICS	CERVICAL VERTEBRAE	THORACIC VERTEBRAE	LUMBAR VERTEBRAE
Spinous process	Short spinous process	Long spinous process	Short spinous process
Transverse process	Wide and short transverse process	Long transverse process	Short transverse process
Centrum	Small centrum	Medium-sized centrum	Large centrum
Transverse foramen	A pair of transverse foramina	No transverse foramen	No transverse foramen

# Joints

- ⇒ Bones are **too rigid** to be bent without breaking
- ⇒ Joints are **points** where **two or more bones meet**, or **cartilage and bones meet**
- ⇒ Flexible connective tissues from joints that hold the bones together so that movement can take place
- ⇒ Most joints allow the bones to move relative to each other
- ⇒ Different types of joints allow different types of movements
- ⇒ Three types of joints
  - I. Immovable joints
  - II. Slightly moveable joints
  - III. Freely moveable joints

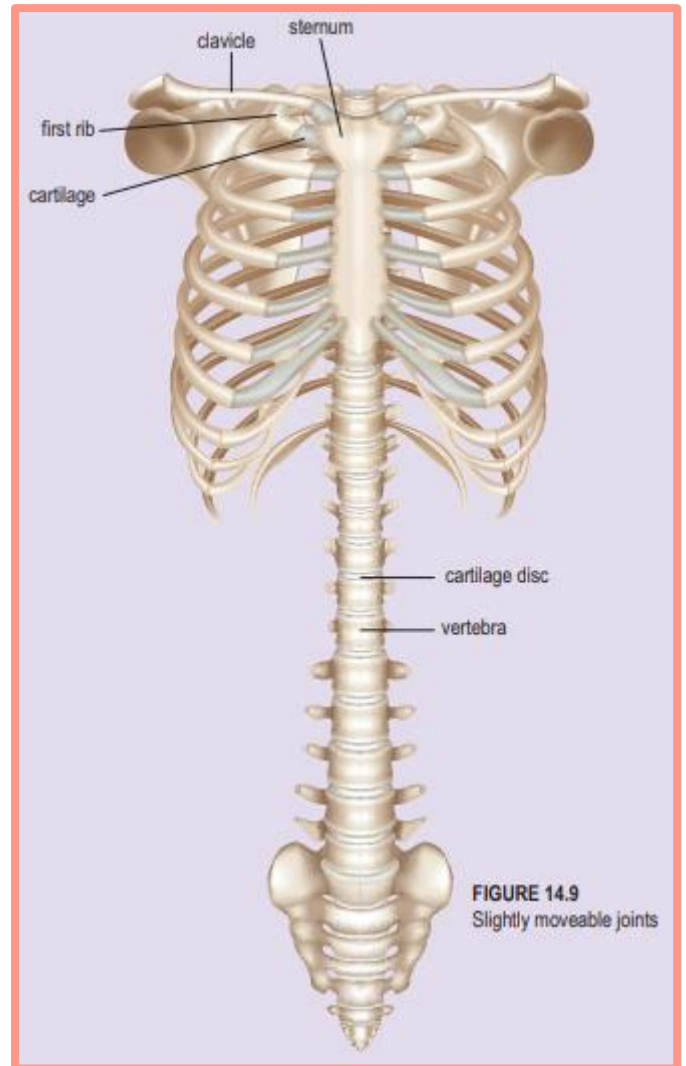
## IMMOVABLE JOINTS

- For example, **suture** at the **cranium of the skull**



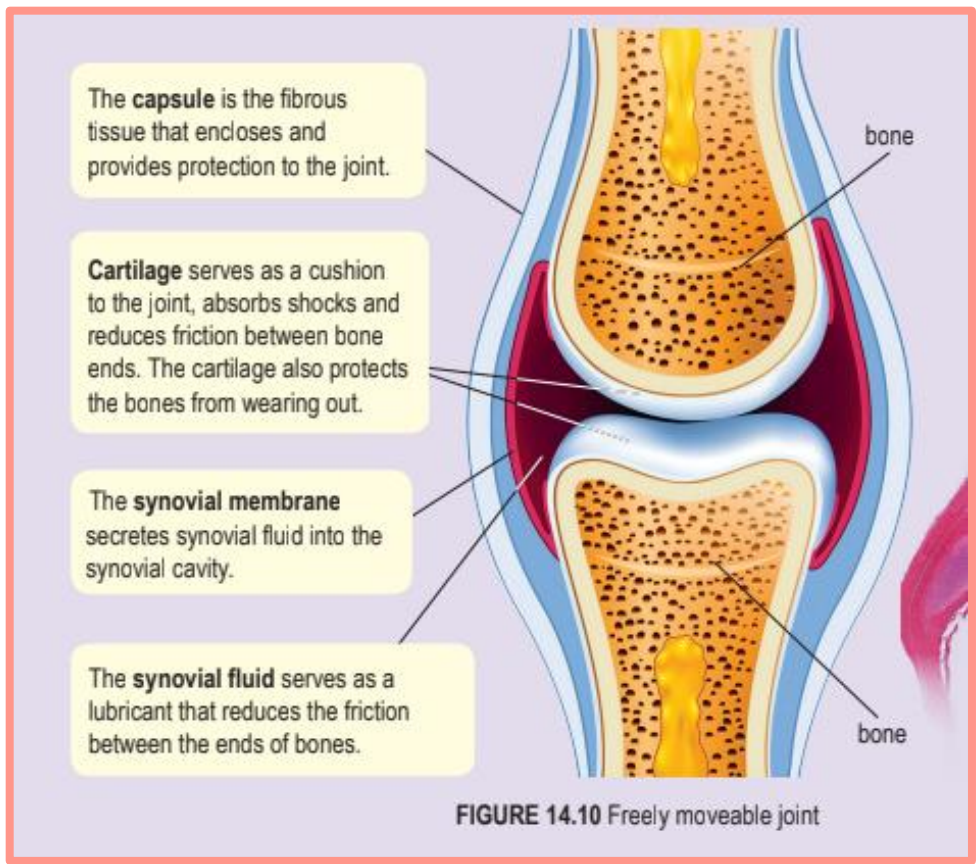
## SLIGHTLY MOVEABLE JOINTS

- ⊕ For example
  - ⇒ **Cartilage discs** between the **vertebrae**
  - ⇒ **Cartilage** between the **first rib and sternum**



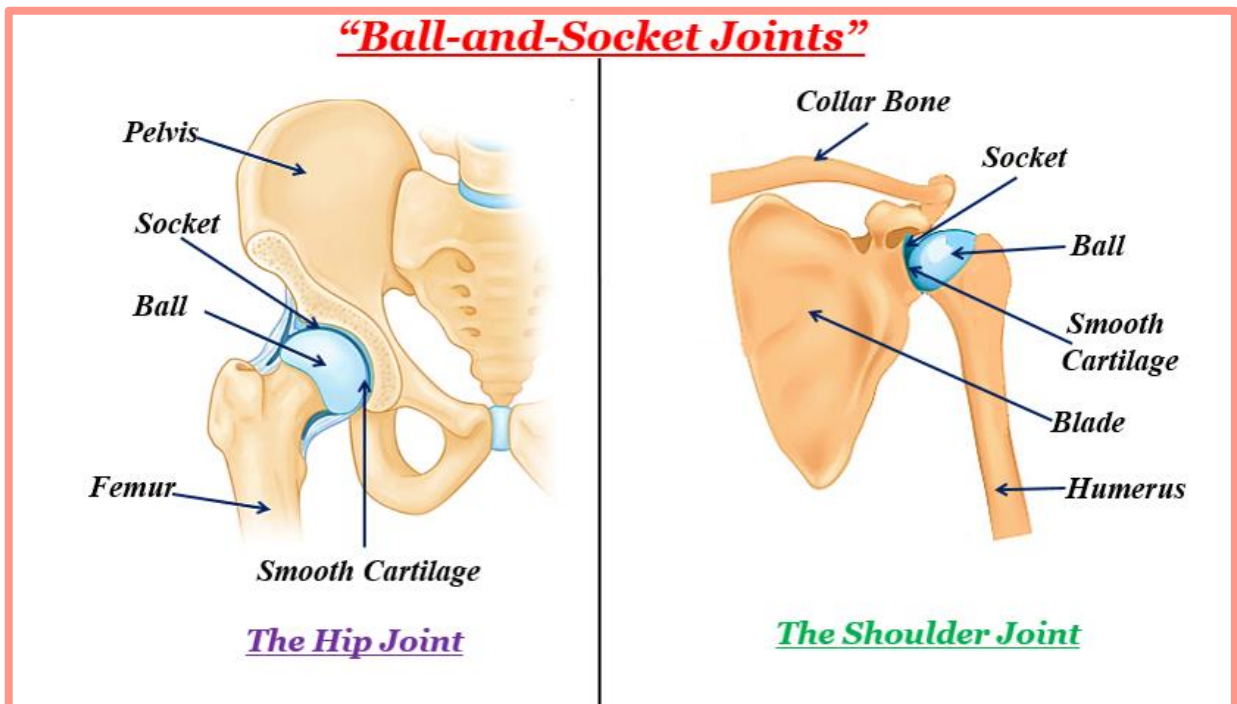
## FREELY MOVEABLE JOINTS

- ◇ For example,
  - ↳ Hinge joint
  - ↳ Ball-and-socket joint



**BALL-AND-SOCKET JOINT**

- ⊞ The **ball-and-socket joint** allows **rational movement** in all **directions**
- ⊞ It allows the arm and leg to **swing** in a **circular motion**
- ⊞ For example,
  - 1) The shoulder joints between the humerus and pectoral girdle
  - 2) The hip joint between the femur and pelvic girdle

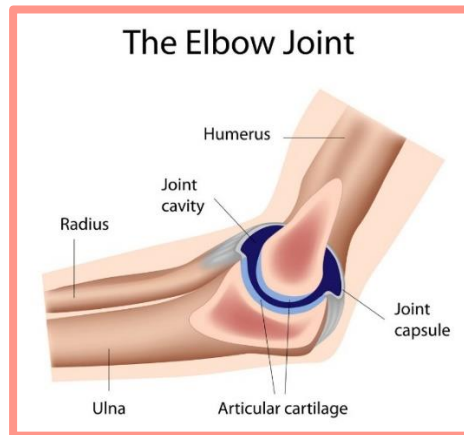
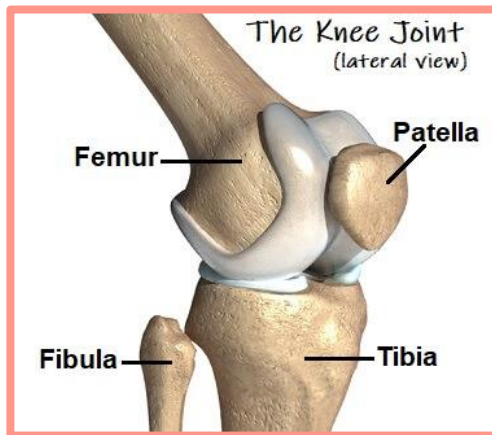


**HINGE JOINT**

→ The **hinge joint** allows the **movement** of **bones** in one plane

→ For example,

1. The knee joint allows the lower leg to swing back and forth, similar to a hinge on a door
2. The hinge joint found at the elbow
3. The phalanges of the fingers and toes also have the hinge joint



**SKELETAL MUSCLE**

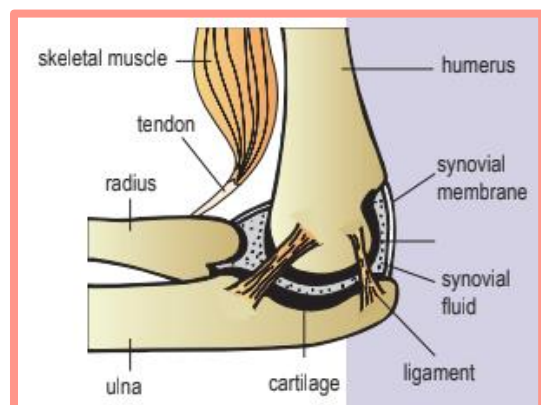
- » Comprises **bundles of muscles fibres**, with a **large supply of nerves and blood vessels**
- » The muscles work in **pairs** and **act in opposite directions**, that is if one muscle contracts, the other relaxes, and vice versa
- » These types of muscles are known as **antagonistic muscles**
- » The biceps and triceps are examples of antagonistic muscles
- » The muscle that **straightens the limbs** when it **contracts** is called the **extensor** (e.g., the triceps)
- » The muscle that **bends the limbs** when it **contracts** is called the **flexor** (e.g., the biceps)

**TENDON**

- + Connects **bone and muscle**
- + Consists of **strong fibres, not elastic but flexible**

**LIGAMENT**

- Δ Connects **bone to bone**
- Δ Bones are **held together** at the joints by the **ligament** which consists of **strong, elastic and tough connective tissue bundles**
- Δ The ligament provides **support** and the **strength** to joints and **allows** bones to be **bent** at the joints



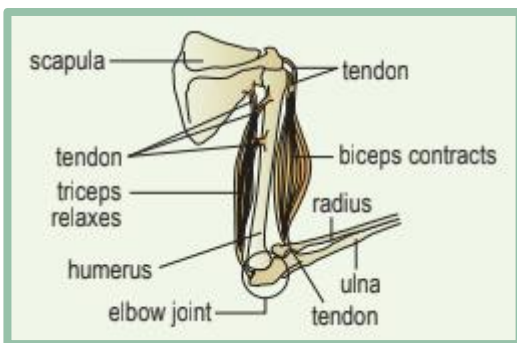
# CHAPTER 14.3 – MOVEMENT AND LOCOMOTION

## Mechanism of locomotion in humans

The action of the muscles results in the movement of the forearm

### ARM BENDING

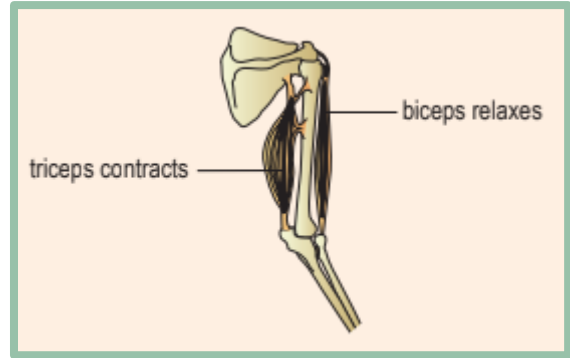
- ⇒ When the biceps contracts, the pull force is transmitted to the radius through the tendon
- ⇒ At the same time, the triceps relaxes
- ⇒ The radius is pulled upwards, causing the arm to bend



### ARM STRAIGHTENING

- ◇ When the triceps contracts, the pull force is transmitted to the ulna through the tendon
- ◇ At the same time, the biceps relaxes

- ◇ The ulna is pulled downwards, straightening the arm



## The action of antagonistic muscles during walking

- ⊕ Leg movement is produced by the action of the antagonistic muscle pair
- ⊕ The biceps femoris is the flexor whereas the quadriceps femoris is the extensor

### STEP 1

- ↳ The right calf muscle contracts, lifting the heel
- ↳ The ball of the foot pushes against the ground

### STEP 2

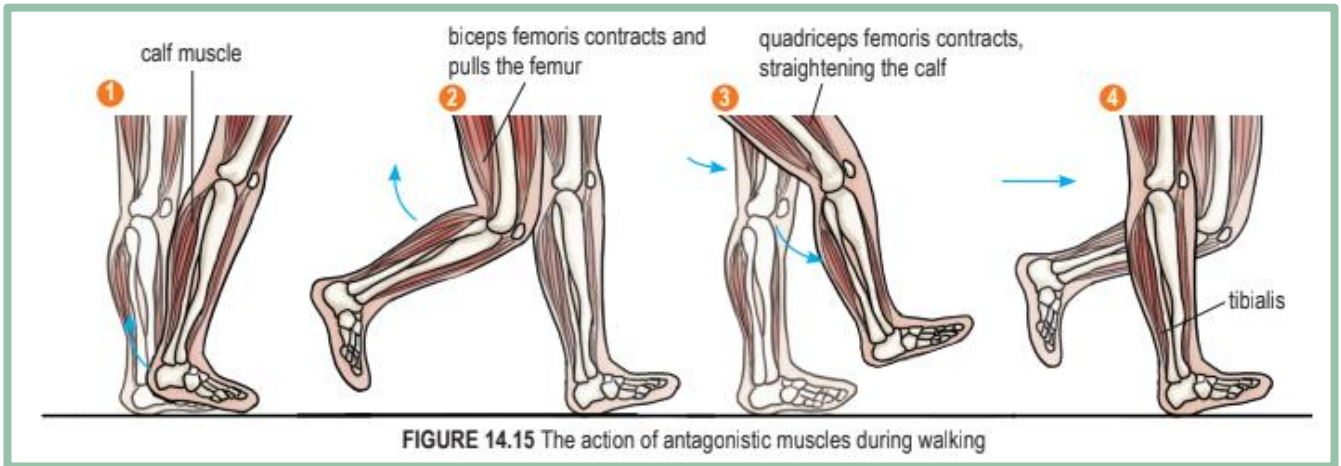
- ❖ At the same time, the biceps femoris contracts, bending the foot at the knee joint
- ❖ The right leg is lifted

**STEP 3**

- ♥ As the right leg leaves the ground, the body weight is now supported by the left leg which is still on the ground
- ♥ The quadriceps femoris (extensor) contracts to straighten the leg

**STEP 4**

- The tibialis contracts to bring down the heel
- As the right heel touches the ground, body weight is shifted to the right leg
- The whole sequence is repeated by the left leg

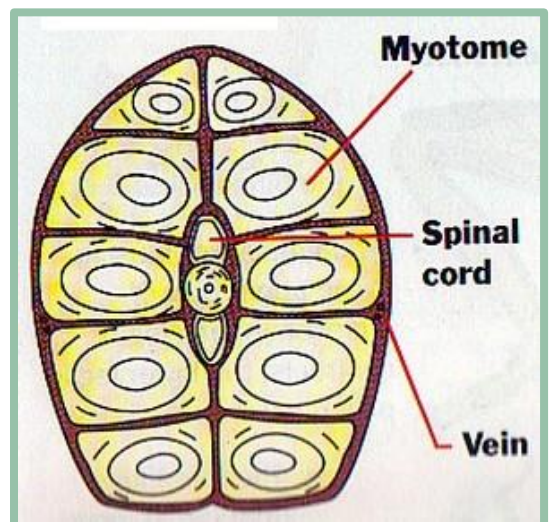


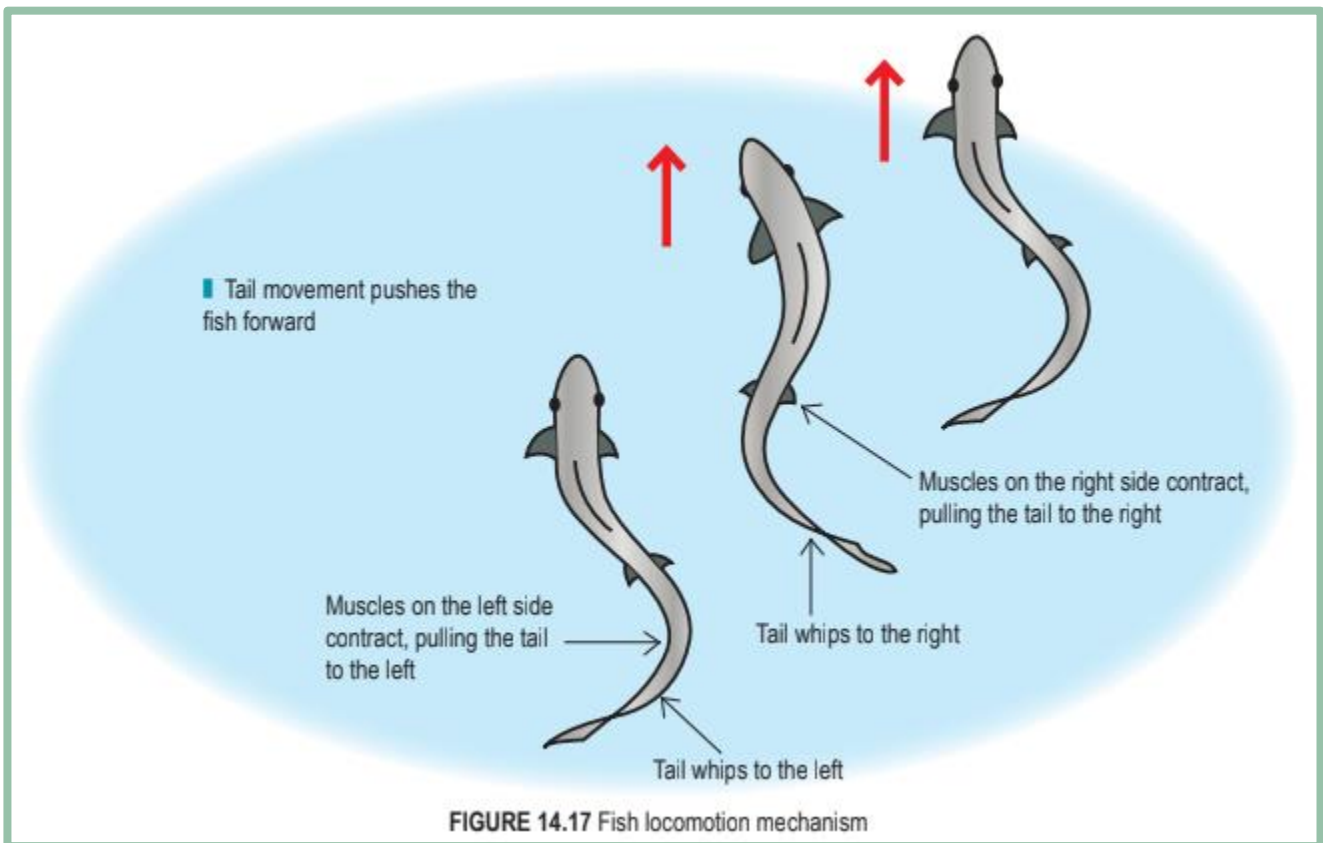
## Mechanism of locomotion in animals

**FISH**

- The fish vertebral column is flexible and can be moved from side to side by the concentration and relaxation of myotome, W-shaped muscle segments
- These antagonistic muscles act in opposite directions
- This enables a fish to whip its tail
- As the myotome on the right contracts, the one on the left relaxes
- The tail will be whipped to the right
- On the contrary, when the right myotome contracts, the left relaxes and the tail is whipped to the left

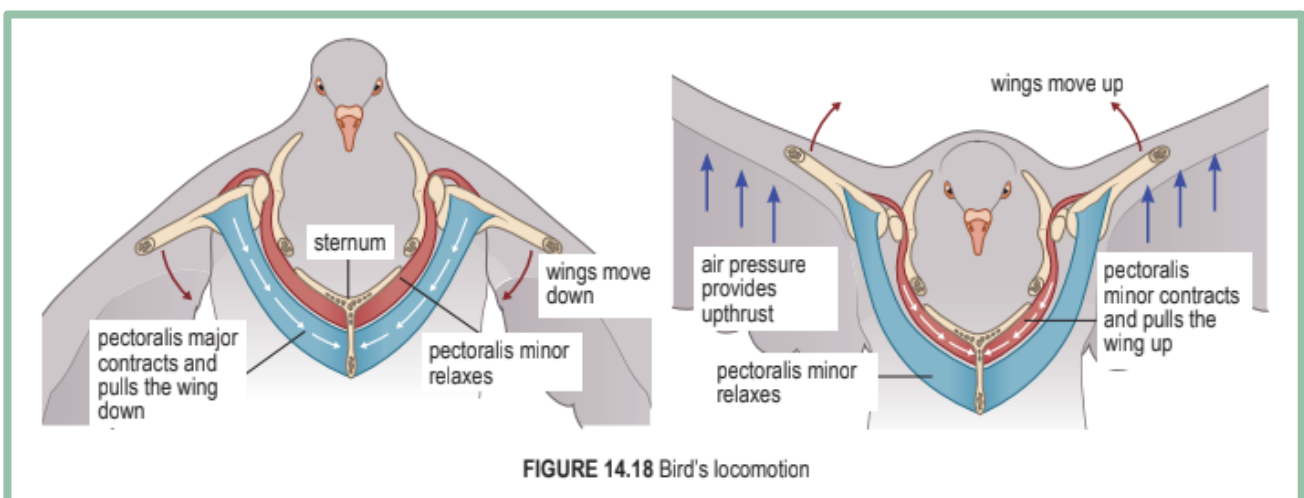
- Alternating waves of contraction and relaxation occur along the myotome
- The action causes parts of the body to move from side to side, pushing water backwards and sideways, and hence moving the fish forward
- The fins are used to control a fish's movement and direction





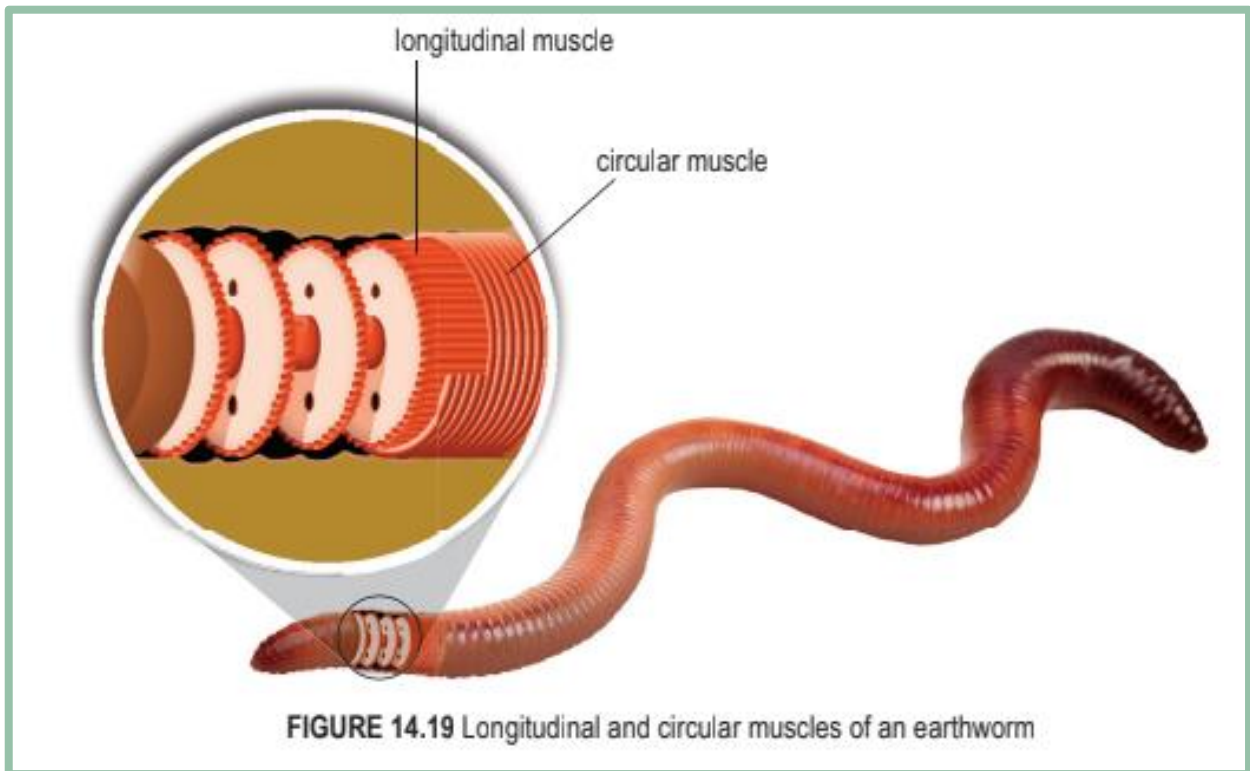
### BIRD (FLIGHT)

- ✓ The action of the large and strong antagonistic muscles on a bird's chest assist in the flapping of the wings
- ✓ When the **pectoralis major contracts** and the **pectoralis minor relaxes**, the wings are pulled down
- ✓ When the **pectoralis minor contracts** and the **pectoralis major relaxes**, the wings are pulled up



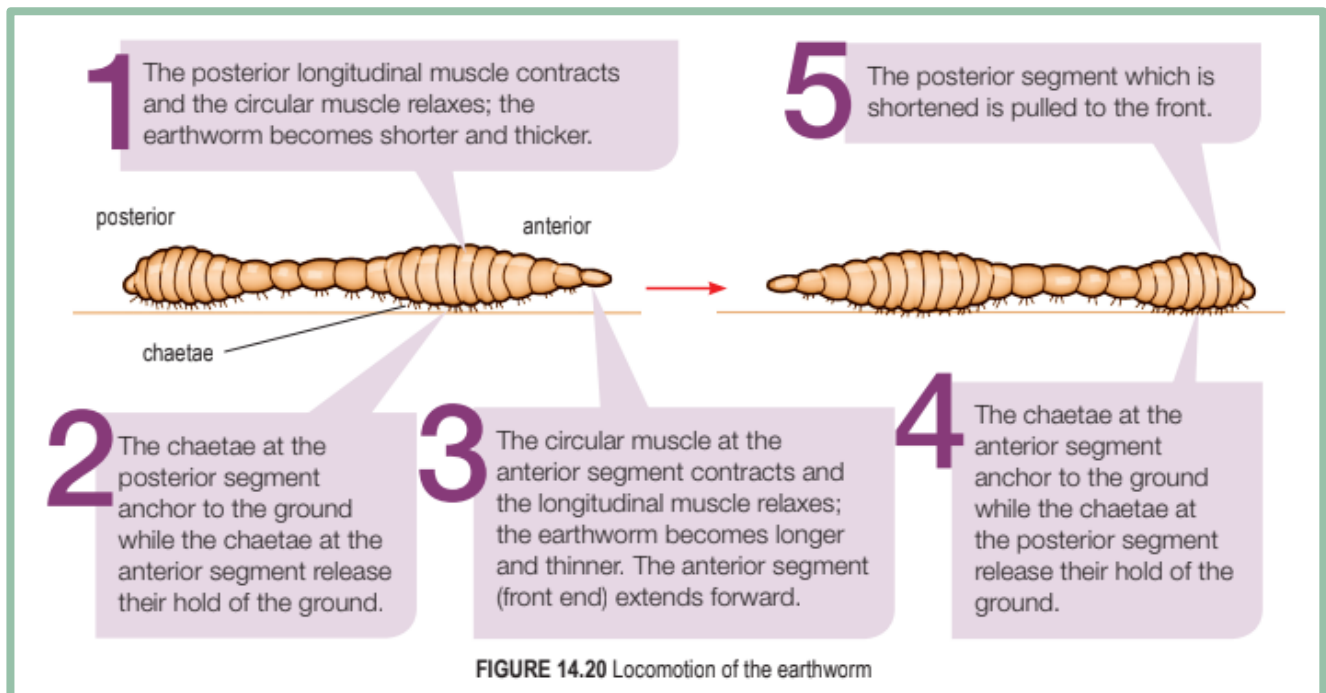
**EARTHWORMS**

- The alternate contractions and relaxations of the circular and longitudinal muscles result in a wave of peristalsis along the body of the earthworm



**FIGURE 14.19** Longitudinal and circular muscles of an earthworm

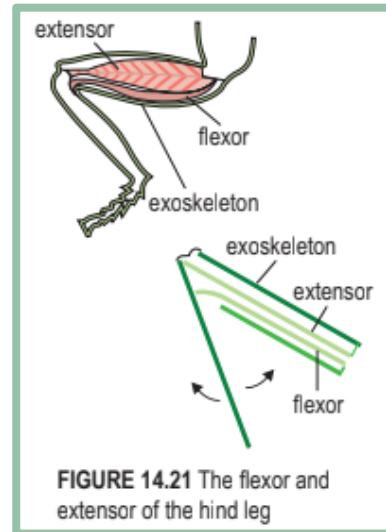
**LOCOMOTION OF THE EARTHWORM**



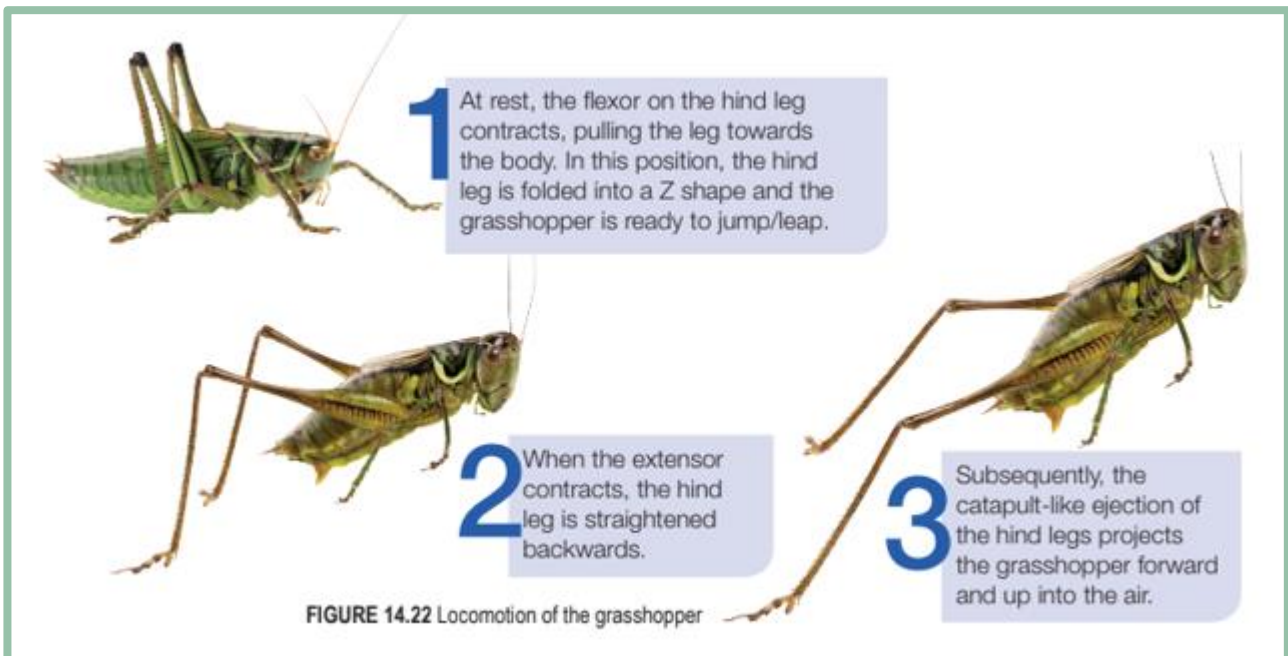
**FIGURE 14.20** Locomotion of the earthworm

## GRASSHOPPER (JUMP/LEAP)

- » The antagonistic muscles of a grasshopper, that is the **flexor** and **extensor** are attached to the **inner surface of the exoskeleton**
- » The **flexor** bends a joint while the **extensor** straightens it
- » The muscular and long hind legs of a grasshopper are adapted for jumping or leaping



## LOCOMOTION OF THE GRASSHOPPER

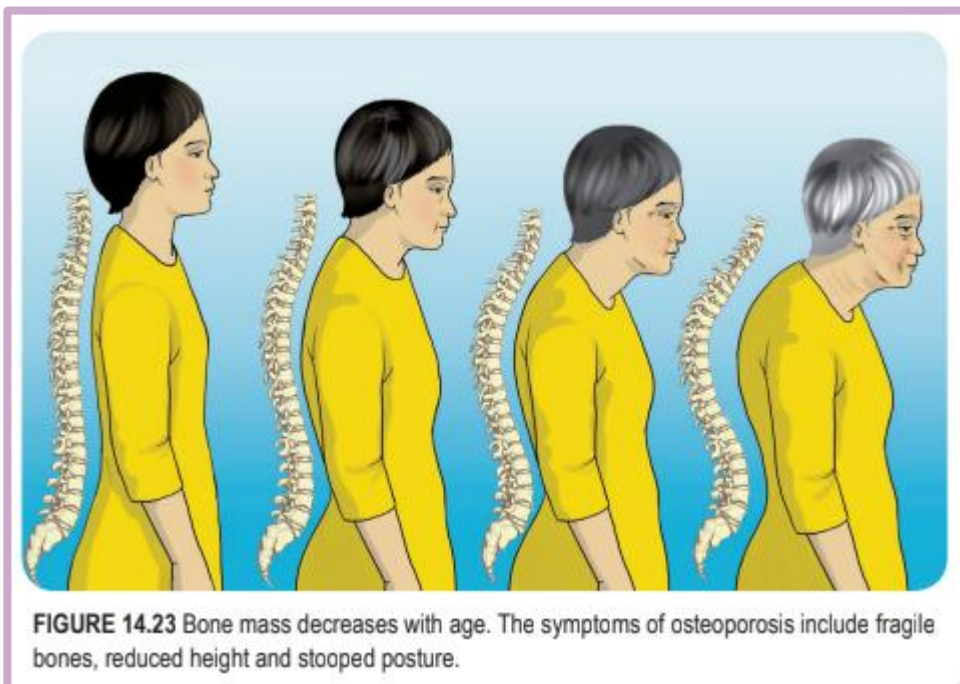


# CHAPTER 14.4 – HEALTH ISSUES RELATED TO THE HUMAN MUSCULOSKELETAL SYSTEM

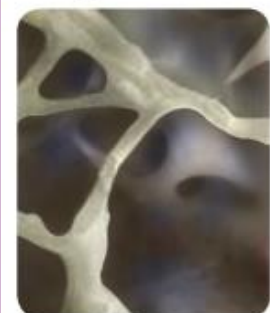
## Health issues related to human musculoskeletal system

### OSTEOPOROSIS

- ◇ Osteoporosis is a bone disorder characterised by weak bones that may break easily
- ◇ As a person ages, the rate of calcium loss is higher compared to the rate of calcium absorption, causing a loss in bone mass or density
- ◇ Among the contributing factors are lack of exercise and low intake of calcium, phosphorus and vitamin D
- ◇ Osteoporosis is common among women who reach menopause because their oestrogen level is decreased
- ◇ Oestrogen is involved in calcium metabolism whereby it helps the body to absorb calcium and reduces calcium loss from the bone
- ◇ A low oestrogen level can reduce bone density due to the loss of calcium from bones



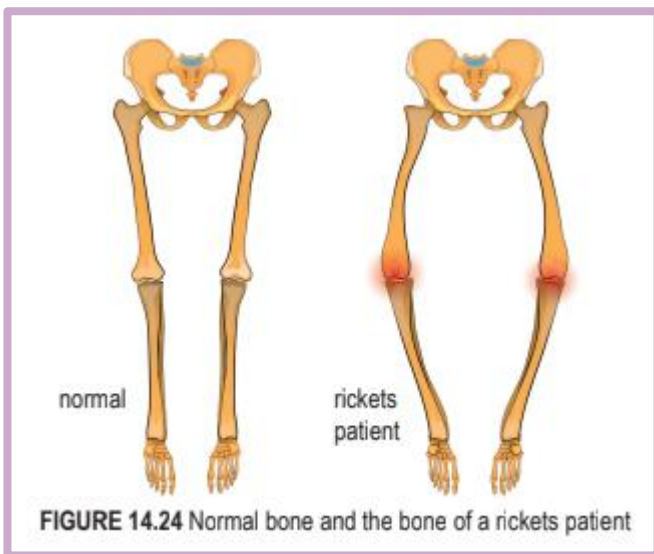
(a) Normal bone



(b) The bone of osteoporosis patient

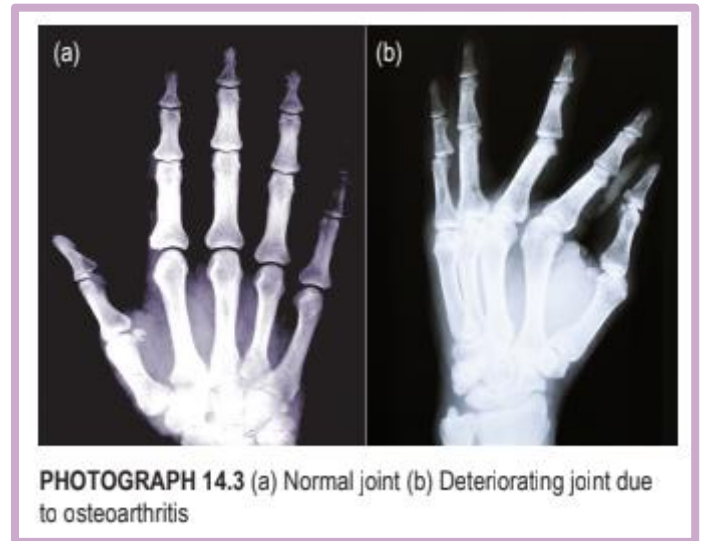
**OSTEOMALACIA**

- Osteomalacia is a soft bone condition due to lack of calcium, phosphorus and vitamin D
- Osteomalacia occurs among adults, especially pregnant woman
- It is called rickets if it occurs among children
- Rickets causes the softening and weakening of children’s bones, resulting in bone defects



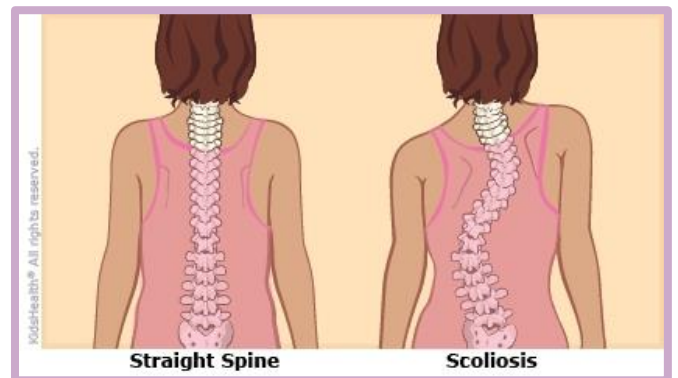**ARTHRITIS**

- ✚ A common type of arthritis among the elderly is osteoarthritis
- ✚ Osteoarthritis is caused by decreased synovial fluid, and wear and tear of the cartilage in certain joints
- ✚ The cartilage becomes thinner, and the ligament shortens and loses some of its elasticity
- ✚ Joints, such as the knee joint becomes swollen, painful and less flexible
- ✚ Arthritis restricts daily activities such as walking



**SCOLIOSIS**

- The backbone of a scoliosis patient is bent to the side, forming an ‘S’ or ‘C’ shape when viewed from the back
- Scoliosis may be caused by a genetic factor or abnormal growth of the backbone during puberty development



*Practices to maintain a healthy musculoskeletal system*

**GOOD BODY POSTURE**

- Posture refers to a person’s body position when sitting, lying, walking and standing

- We should not slouch when standing or sitting
- Slouching will exert pressure on the vertebral column, resulting in the misalignment of the vertebral column
- This will prevent circulation of the blood, suppressing the nerves and vital organs

**PROPER ATTIRE**

- ❑ Wear proper, comfortable and loose clothing so as not to restrict blood circulation and affect the musculoskeletal system
- ❑ A suitable pair of shoes, with low heels and cushion, provides support and prevents injury to the vertebral column

**EXERCISE**

- ⇒ Exercise strengthens the joint structure and increases the flexibility of muscles and ligaments
- ⇒ Exercise also increases bone strength and bone mineral deposits among adults, as well as prevents osteoporosis in the elderly

**BALANCED DIET**

- ⊞ Consume a balanced diet, especially foods rich in
  - ⊕ calcium (milk)
  - ⊕ minerals (phosphate)
  - ⊕ vitamin C
  - ⊕ vitamin D
- ⊞ vitamin D aids in calcium absorption, while vitamin C increases bone mass

